



CANINE HIP DYSPLASIA

Hip dysplasia is the abnormal development of the hip or coxofemoral joint. The hip joint is a ball and socket type of joint and in the normal joint, the ball (femoral head) should fit snugly in the socket called the acetabulum. Dogs which have hip dysplasia have or have had hip joint laxity of varying degrees from a very early age. Young patients may have partial or complete luxation (dislocation) of the femoral head from the acetabulum while older patients show mild to severe arthritic changes in the hip joints. The laxity of the hip joints in the younger dogs may go unnoticed in some while others show discomfort, lameness, difficulty rising after rest, exercise intolerance, and a reluctance to run and jump. Some young dogs will appear to improve and may appear normal for months or years. This is believed to be due to fibrosis or scarring secondary to inflammation which seems to help stabilize the joint. However many of these dogs present later in life with severe arthritis and clinical signs of discomfort and lameness. It should also be noted that there are many dogs which may have a radiographic diagnosis of hip dysplasia but which are clinically normal.

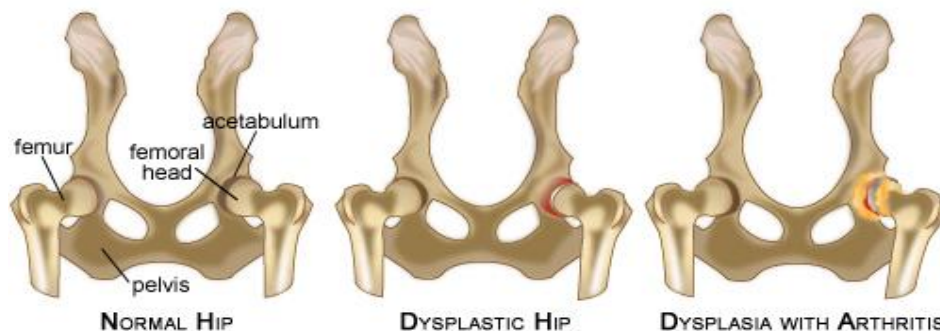


Photo credit: doghealth.com

The cause of hip dysplasia is primarily genetic but development is influenced by other factors. Significant ones are the weight and growth of pups as well as nutrition. Heavier rapidly growing pups have a higher incidence of hip dysplasia at maturity. Pups fed diets high in calcium and vitamin D are more likely to develop hip dysplasia. There is good evidence that feeding high certain quality large breed puppy foods reduces the incidence of hip dysplasia and other juvenile bone disorders. These foods are normally restricted in calories to prevent obesity in puppies and slow the rate of growth during the critical period of bone development. They also are restricted in calcium and vitamin D to meet but not exceed requirements. High calcium levels can delay bone maturation in puppies and lead to hip dysplasia.



While hip dysplasia is most common in large breed dogs, it can also be seen in small breeds and cats. It is interesting that some breeds such as Greyhounds have an extremely low incidence of hip dysplasia.

The orthopedic examination of the dog may leave the veterinarian with strong concerns about hip dysplasia but the diagnosis is confirmed with radiography. Dog owners may have radiographs submitted to the Orthopedic Foundation for Animals (OFA) for grading and certification for breeding purposes. The grading system rates the hips as excellent, good, fair, borderline, mild dysplasia, moderate dysplasia and severe dysplasia. Dogs must be at least 24 months of age to be certified.

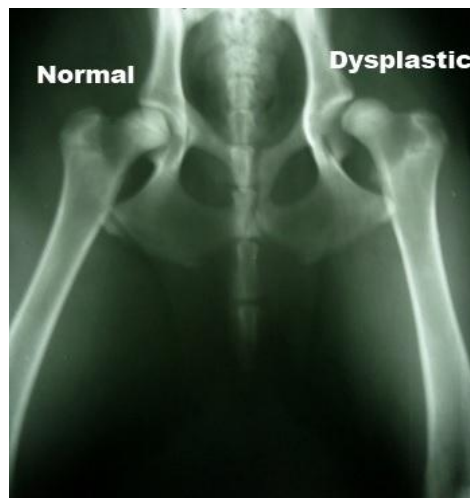

Photo credit: nemda.org

The treatment of hip dysplasia is either medical (nonsurgical) or surgical. Medical treatment involves weight control and exercise in moderation, plus the use of chondroprotectants such as glucosamine, pain relieving drugs, and anti-inflammatory medications.

Surgical treatment may include:

- 1) a preventive intervention called juvenile pubic symphysiodesis in immature dogs between 12 and 16 weeks of age.
- 2) pelvic ostectomy in immature dogs to capture more of the femoral head by the acetabulum.
- 3) femoral head and neck ostectomy whereby the femoral head and neck are excised.
- 4) total hip arthroplasty or hip replacement surgery.

There are many factors to be considered when selecting a form of treatment and consultation with a veterinarian with experience with this problem is required.

Breanne Galloway, D.V.M
Teresa Millar, D.V.M
Margaret Fisher, D.V.M
Katelyn Behm, D.V.M

100 - 7020 Francis Road
Richmond, BC V6Y 1A2
stevestonvethospital.com
604-274-9938
admin@stevestonvethospital.com